

## Studies on haemopoiesis and histological aspects of *Rana ridibunda spleen*

Abdul-majeed H. AL-saffar

Department of Basic Science. College of Dentistry. Babylon University / Iraq

### الخلاصة

تم اختيار عشرون ضفدع *R. ridibunda* من كلا الجنسين بحالة جيدة من تجمعاتها الاعتيادية مثل (الأماكن العامة والحدائق ومن مجمع جامعة بابل) لغرض إجراء دراسة على الطحال وتقديم الوصف الدقيق لهيئته ودراسة تاريخ التطور الجنيني ومكونات الدم في داخله. لقد بينت الدراسة الحالية إن الطحال ظري الملمس وشكله كلوي أو بيضاوي يشبه حبة الفاصوليا مع ملاحظة وجود انبعاث ظهري- بطني في بعض الحالات. لون الطحال في الغالب احمر أو ماروني . موقع الطحال داخل التجويف البطني يكون متصلا بمسار يق ألفتافي اوالاتنى عشري(الأمعاء الدقيقة) قريبا من مقدمة نهاية المستقيم . التركيب النسيجي للطحال يتألف من كيس أو غلاف خارجي (capsule) وهو عبارة عن نسيج رابط يعرف بالكبسولة يغطي الطحال. المقطع العرضي للطحال تحت الميكروسكوب عبارة عن سطح احمر اللون لا تظهر عليه حدود واضحة تفصل بين اللب الأبيض (white pulp) مع اللب الأحمر (red pulp) وهذا الأخير يحيط باللب الأبيض ويحتوي على كريات دم حمراء وخلايا بلعمية (macrophages). وظيفة هذه الخلايا التهام وتكسير كريات الدم الهزيمة. أما اللب الأبيض فيكون دائري غير واضح المعالم ويحتوي خلايا لمفية تتشابه وظيفيا مع نظيراتها من خلايا الغدة اللمفية. وجود فجوات وثغرات مملوءة بالدم وحزمت من الخلايا بين اللب الأحمر (red pulp) و اللب الأبيض (white pulp) . الطحال في شعبة اللاذئبيات تكون خلال المراحل الجنينية من نفس الأصل الذي تكون منه الطحال في اللبائن. وجود خلايا دموية ولمفاوية لمراحل تكوينيه مختلفة منها ناضجة وبالغة وحتى الأصيل (precursors) موجودة تحت الغلاف (sub capsular) مما يثبت بأن تكوين الخلايا الدموية في هذه الحيوانات يحدث في هذه المنطقة. يظهر الطحال في بعض الأحيان وكأته عبارة عن كيس مملوء بالدم مما يؤيد بان للطحال القابلية على تصفية وعزل المكونات الدموية وإرجاع مكونات الحديد التي تدخل في إعادة بناء كريات دم جديدة ولذلك يعتبر بأنه جهاز لمفوي ودموي مملوء بالدم .

### ABSTRACT

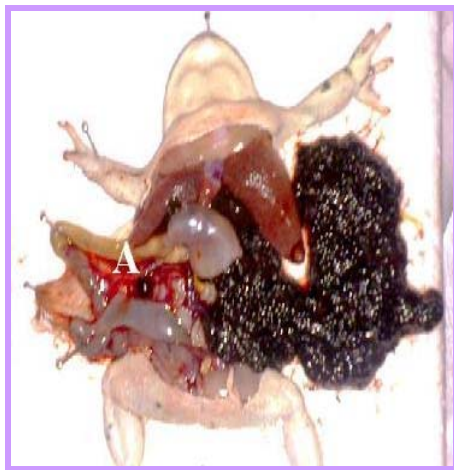Twenty frogs of *R. ridibunda* species apparently healthy of both sex were chosen throughout their normal assemble meeting (i.e. Babylon University campus, domestic places and gardens). Their spleen is located in the mesentery of ileum or ileu-dodeunal area posterior to the anterior end of cloacae. It is connected to the mesentery of small intestine by the spleen artery and visceral lymphatic. The spleen consistency is soft, fluffy with a bean like shape or oval to globular shape in some instances with dorso-ventral depressions at both sides. The organ's color is red to maroon red. The spleen is encapsulated by a connective tissue capsule. Histological picture reveals a red soft surface shows two areas with no obvious border, the white pulp and the red pulp. The red pulp surrounds the white pulp and contains mainly red blood cells and macrophages. The main function of the red pulp is to phagocytes old red blood cells. The white pulp is circular in structure and is made up of lymphocytes it functions in a manner similar to the cells of the lymph nodes. The observed precursors,

intermediate as well as mature cells of erythroid, myeloid and lymphoid series in the sub capsular spaces, indicating extramedullary haemopoiesis. At some times the spleen appears as a connective tissue sac filled with erythrocytes which may indicates its ability for blood filling. Thus spleen in these vertebrates is haemolymphoid, and also blood filtering organ.

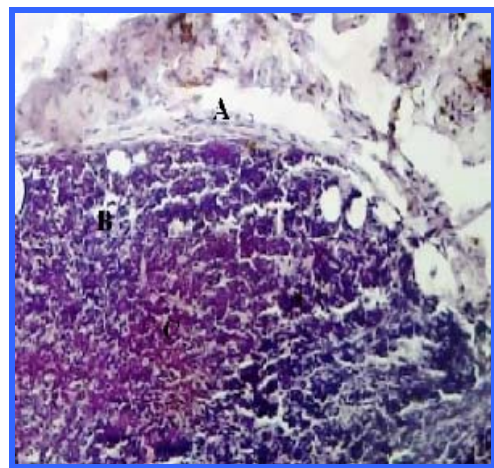
## INTRODUCTION

The spleen is vertebrate organ which is closely associated with the circulatory system. It is derived from mesenchyme and lying in the mesentery. The spleen consists of masses of lymphoid tissue of granular appearance located around the terminal branches of veins and arteries. Spleen serves an important role in haemopoiesis and generation of primary immune response, it functions in the destruction and sequestering the old red blood cells from circulation and reutilizing the iron portion of their hemoglobin and discard the debris from bloodstream, <sup>1,2,3</sup>. The internal support of the spleen (trabaculae) gave the possibility for spleen to undergo contractions therefore it is acting as blood volume regulator<sup>4</sup>. The spleen also considered as important store-house in holding a reservoir of blood and lymphocytes <sup>4,5</sup>.

During hibernation the spleen generates lymphocytes and serves as a site for haemopoiesis <sup>6,7</sup>. Spleen structures of other anurans such as *Xenias*, *Laevis*, and *buffo marinus* were documented. However *R. ridibunda* spleen was not been tackled <sup>6,7</sup>. The aim of the present study work undertaken to report and document some information about the shape, color and size of spleen as well as the history and to proof evidence for extramedullary haemopoiesis in *R. ridibunda* an Iraqi frog species .



(Fig1) **A**. The location of the spleen in the mesentery.



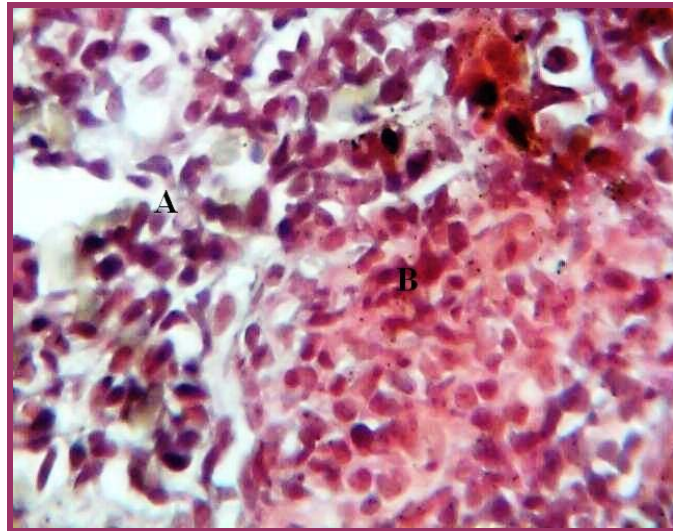
(Fig2) **A** connective tissue capsule .**B**. red pulp  
**C**. White pulp.

## MATERIALS AND METHOD

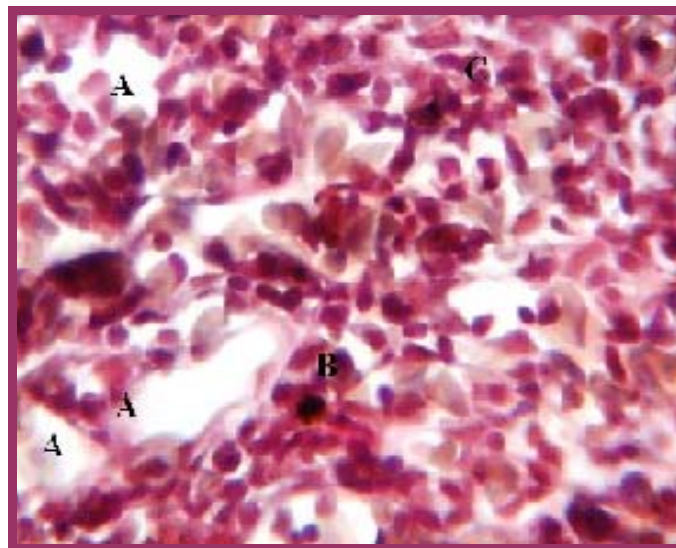
Twenty frogs of *R. ridibunda* species were anesthetized for enough time with flu. Ethan (ICI UK) at all not more two minutes in a conditioned poly rectangular cupping polyethylene jar. Frogs divided at random into two groups, ten of each group. The first group methodically dissected according to Minkoff procedure<sup>8</sup> to confirm and register the spleens locality, shape, color and consistency by a naked eyes. The frogs killed to prepare their spleen for histological sectioning and staining in the same manner of Dacie and Lewis<sup>9</sup>. The second group injected subcutaneously in the abdomen 1/2 ml of diluted Indian ink 1:5 v/v<sup>10</sup>. After 30 minutes these frogs were killed to verify their spleen about the destiny of the injected Indian ink. The spleens of both groups collected and dissected longitudinally and transversely, finally the dissected pieces fixed by Bouin's fixative solution<sup>11,12</sup>. The pieces washed thoroughly with water and processed by automatic tissues processor then embedded in paraffin wax. Spleen pieces were sliced by a microtome, each about 3-4 $\mu$  thickness. The slices fixed on glass slides and stained by Harris haematoxylin-eosin stain<sup>11</sup>. All the stained slides examined microscopically to observe the normal histological structures and the abnormal changes in spleen parenchyma due to the injected Indian ink.

## RESULTS

The spleen of *R. ridibunda* is located in the mesentery of ileum or ileu-dodenal area posterior to the anterior end of cloacae (Fig1). Their main staple is soft fluffy oval to bean shaped with upper and lower depression on both sides. Their normal color varies from red to maroon red. They are connected to the mesentery of small intestine by spleen artery and visceral lymphatic. The organ turned to reddish black color post injection of 1/2 ml Indian ink. Histology of the spleen reveals outer envelope of a connective tissue capsule, parenchyma or the inner core of the organ composed of two pulps named red which is not clearly divided from the white pulp (Fig2). The inner portion is the white pulp which contains high population of lymphocytes, these population may form sheath like pattern around the spleen artery. Red pulp contains abundant numbers of erythrocytes. Blood cells filling lacunae were observed in the examined slides (Fig3).



(Fig3) A. red blood cells B. lymphocytes



(Fig4) A. mopped areas B. macrophage Phagocytize Indian ink .C .RBCs

Some of the vascular system appears as a wide lumen with a thin wall which is composed of phagocyte cells, representing the elongated reticulo-endothelial cells. The spleen in some frogs composed of a connective tissue sac filled with erythrocytes. Other slides show mopped areas as it appear in some sections stained by haematoxylin-eosin stain. Precursors of lymphoid and erythroid series were seen with various forms as lymphoblast and erythroblasts, (Fig4). This was an evidence of haemo-lymphatic activity of this organ.

## DISCUSSIN

*Rana ridibunda* spleen was not documented previously by any researcher as other species were dealing by some studies<sup>4,7</sup>. The present work aiming to report and document the basic structures, function of *R. ridibunda* spleen. In comparasion with mammalian spleen (trabaculae and follicles) were well registered however yet still in *R. ridibunda*, the reported histological examination reveals that the cell bundles which appear to separate the white pulp from the red pulp of *R. ridibunda* spleen were similar to that observed in the mammalian organ<sup>7</sup>. The lacuna of *R. ridibunda* spleen was filled with blood, while it was absent in mammalian spleen Cooper<sup>4</sup> denoted and declare the same. The observed mopping views in the examined sections of spleen tissues indicates that spleen posses the blood filtering ability according to the presence and absence of the blood in the organ, also the same results was indicated<sup>4</sup>.

Available variant stages of haemopoiesis observed in the examined spleen slices. Andrew<sup>6</sup> also noticed and proved that the extra medullary haemopoiesis in the organ of amphibians, Other<sup>7</sup> supports this declaration. The presence of lymphoblast and plasma cells indicate the lymphoid nature of this organ these observations were confirmed by others<sup>4,5</sup>. The wide lacunae with phagocyte cells trapping the Indian ink suggest its role as phagocytic organ. Another studies<sup>4,7</sup> sustained the results of this experimental observation. Scalia et.al<sup>14</sup> also demonstrated that the spleen pigment cells of amphibian are macrophages.

The spleen is haemopoietic organ since the presence of immature, stem cells as well as mature forms were noticed by Goryshina<sup>15</sup> and he reported the same observation on grass frog during hibernation, and lymphoid organ due to the presence of large lymphocytes population. While Rafael<sup>16</sup> mention that the red pulp of *R. perezi* displays two different portions, the predominant region consist of reticular cells, lymphocytes and a variety of other leucocytes, also cells undergoing division, Therefore this area possibly performs a haemopoietic function. The smaller portion of the red pulp is characterized by reticular-phagocytic cells and may be haemocaretic in its function. Blood filtering organ due to the spleen appearance as a capsule or a sac filled with erythrocytes. On the other site the spleen is a phagocytic and trapping organ due the presence of phagocyte cells phagocytize the Indian ink 30 minutes after injection. Thus on summing up the conclusion the spleen can plays the mentioned above roles which confirms and verify the results of the present study on the spleen of Iraqi species *R. ridibunda*.

## REFERENCE

- 1-Van Rooijen, N., Claassen, E., Kraal, G. and Dijkstra, C.D. (1989). Cytological basis of immune function of the spleen. Progress in Histochem.Cytochem.19, 1-69.
- 2-Zapata, A.G. and Cooper, E.L. (1990).The Immune System: Comparative histophysiology.New York: Johns Wiley and Sons.
- 3-Andrea Brendolan, Elisabeth Ferretti, Valentine Salsi, Kelvi Moses, Susa Quaggin, Francesco Blasi, Michael L.Cleary and Licia Selleri.

- 4-Cooper, E.L. (1980). General Immunology.Pergamon Press Oxford, 243-256.
- 5-Weiss, L. The Cells and Tissues of the Immune System, Structure, Function and Interactions, Prentic-Hall Inc. Englewood Cliff N.I. 49-70.
- 6-Andrew, W. (1965). Comparative Hematology. Grune and Startton New York 909-103.
- 7-Manning, M.J. and Turner R.J. (1976). Comparative Immunology Blackie London 89-115.
- 8-Minkoff, Eli. C. (1975) a laboratory Guide to Frog Anatomy. Pergamon Press Inc .New York.
- 9-Dacie, J.V. and Lewis, S.M. (2006). Practical Hematology. 10th. Ed. Churchill Living Stone.
- 10-Kinmonth JB (1968) Lymphography, Review of some technical points of the lymphoid system special edition of lymphography, George Theime Publishers Stuttgart.
- 11-Luna, L.G (1968) Manual of histological staining of armed forces.Institut of pathology.3rd Ed. McGraw-Hill Book Company New York.
- 12-Humason G.L. (1967) Animal tissue technique.W.H.Freeman and Company San Franciso.USA
- 13-Sasak K.and Matsumura G. (1988) Spleen lymphocytes in the mouse embryo J.Anta.160 27-37.
- 14-Scalia M.Di Pietro C.Poma M. Ragusa M. Sichel G. Corsaro C. (2004) the spleen pigment cells in some amphibian .Pigment Cell Res.17 (2):9-27.
- 15-Goryshina, EN. (1983) Comparative analysis of seasonal changes in the haemopoietic processes in the spleen and peripheral blood of common frog.II.series Tsitoloiiia. 25(6): 667-77.
- 16- Rafael Alvarez. (2005) an ultrastrctural study of the spleen of Ranid frog Rana perezi .Journal of Morphology 204(1):25-32.